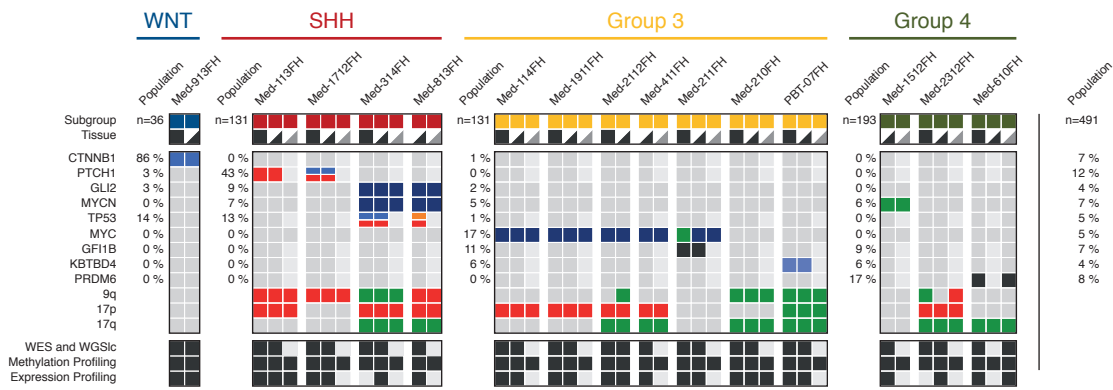
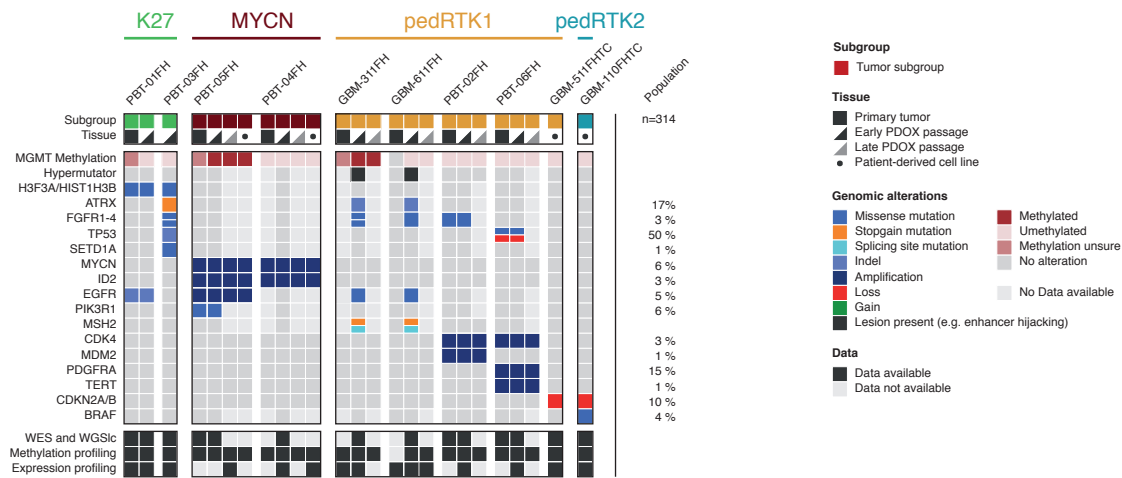


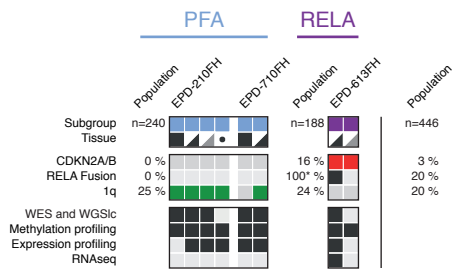
## Medulloblastoma



## High-grade glioma



## Ependymoma



## Atypical teratoid/rhabdoid tumor

